



Object-action dissociation: A voxel-based lesion-symptom mapping study on 102 patients after glioma removal

Alberto Pisoni^{a,b,1}, Giulia Mattavelli^{a,b,1}, Alessandra Casarotti^c, Alessandro Comi^a, Marco Riva^c, Lorenzo Bello^{c,d}, Costanza Papagno^{a,e,*}

^a Dipartimento di Psicologia, University of Milano-Bicocca, Piazza dell'Ateneo Nuovo 1, Milano 20126, Italy

^b NeuroMi (Neuroscience Center), University of Milano-Bicocca, Italy

^c Unit of Oncological Neurosurgery, Humanitas Research Hospital, via Manzoni 56, Italy

^d Department of Oncology and Hemato-Oncology, Università degli Studi di Milano, via Festa del Perdono 7, Milano 20122, Italy

^e CIMeC, CeRiN, via Matteo del Ben 5/b, University of Trento and Rovereto, Rovereto 38068, Italy

ARTICLE INFO

Keywords:

Object action dissociation
Temporal lesion
Frontal lesion
Voxel-based lesion symptom mapping

ABSTRACT

Data concerning the neural basis of noun and verb processing are inconsistent. Some authors assume that action-verb processing is based on frontal areas while nouns processing relies on temporal regions; others argue that the circuits processing verbs and nouns are closely interconnected in a predominantly left-lateralized fronto-temporal-parietal network; yet, other researchers consider that the primary motor cortex plays a crucial role in processing action verbs. In the present study, one hundred and two patients with a tumour either in the right or left hemisphere were submitted to picture naming of objects and actions before and after surgery. To test the effect of specific brain regions in object and action naming, patients' lesions were mapped and voxel-lesion-symptom mapping (VLSM) was computed. Behavioural results showed that left-brain damaged patients were significantly more impaired than right brain-damaged patients. The VLSM showed that these two grammatical classes are segregated in the left hemisphere. In particular, scores in naming of objects correlated with damage to the anterior temporal region, while scores in naming of actions correlated with lesions in the parietal areas and in the posterior temporal cortex. In addition, VLSM analyses carried out on non-linguistic tasks were not significant, confirming that the regions associated with deficits in object and action naming were not generally engaged in all cognitive tasks. Finally, the involvement of subcortical pathways was investigated and the inferior longitudinal fasciculus proved to play a role in object naming, while no specific bundle was identified for actions.

1. Introduction

Several neuropsychological studies have investigated the noun/verb dissociation at a functional or anatomical level to verify whether the processing of distinct grammatical classes is segregated or spread over a common network. Verb-noun dissociation in aphasic patients was first described around 1980 (Baxter and Warrington, 1985; Miceli et al., 1984, 1988; Zingeser and Berndt, 1990). After these preliminary observations, many studies replicated this double dissociation, showing that patients with lesions in the neocortical temporal areas are impaired at naming nouns relative to verbs and patients with frontal lesions are impaired with verbs relative to nouns (for review see Pillon and d'Honinchtun, 2011).

Therefore, this popular view based on neuropsychological data suggests that nouns would require the involvement of left temporal

regions, while left posterior inferior frontal areas subserve verb processing (Damasio and Tranel, 1993), a result replicated in neurodegenerative conditions by Daniele et al. (2013) and, more recently, in neurosurgical patients during awake surgery (Lubrano et al., 2014). This neuro-anatomical distinction traces back the “old” observation that Broca's aphasics with pre-rolandic lesions are more impaired in action naming while fluent aphasics with retro-rolandic lesions are especially affected in naming objects (Goodglass et al., 1966). However, there are exceptions to it, as, for example, the patient reported by De Renzi and Di Pellegrino (1995) with a lesion extending to the frontal lobe but sparing action naming or those described by Silveri and Di Betta (1997) with selective verb impairment and a left parietal lesion. Similar results were obtained in a study mapping lesions of 20 stroke patients: those with disproportionate impairment of verbs clustered mainly in two sites: either left posterior temporal lobe and inferior

* Corresponding author at: CeRiN (Centre for Neurocognitive Rehabilitation), University of Trento, via Matteo del Ben 5/b, 38068 Rovereto, Italy.

E-mail address: costanza.papagno@unimib.it (C. Papagno).

¹ These authors equally contributed to the study.

parietal lesions, or extensive left fronto-temporal lesions (Aggularo et al., 2006). Similarly, Luzzatti et al. (2006) found that in 15 patients with a predominant impairment of verbs, lesions involved the left posterior temporo-parietal perisylvian region, the insula and/or the basal ganglia, but never concerned the frontal lobe only.

This variability found in post-stroke patients is also present in neurosurgical patients. Corina et al. (2005), for example, investigated the neural representation of action verbs and object nouns in 13 neurosurgical patients undergoing awake cortical mapping. Cortical stimulation of the anterior superior and of the middle temporal gyrus caused inability to name objects, whereas the location of the area causing inability to name actions varied across subjects (middle superior temporal gyrus, supramarginal gyrus, and/or the posterior middle temporal gyrus).

The neuroimaging literature is even more inconsistent, due to the different paradigms applied. In general, data seem to confirm the frontal activation for verbs (Petersen et al., 1989; Shapiro et al., 2005; Warburton et al., 1996). However, several studies instead found a posterior middle temporal gyrus activation showing equally strong selectivity for event and state verbs relative to semantically matched nouns (see, for example, Peelen et al., 2012).

Direct evidence for a noun–verb difference can be found in a PET experiment, using lexical decision (Perani et al., 1999). Stimuli selected by Perani et al. were nouns referring to tools and psychological states or manipulation and psychological verbs. Their results showed in completely overlapping neural substrates for verb and noun processing, without a double dissociation between frontal and temporal cortex, but only the presence of areas specific for verbs (Broca's area, left middle temporal gyrus). Other areas, centred on the left perisylvian cortex, were equally activated by noun and verb processing. However, a subsequent PET experiment failed to confirm this result (Tyler et al., 2001): no differences were found between closely matched nouns and verbs. Accordingly, Liljeström et al. (2008) in an fMRI experiment with healthy volunteers who silently performed both action and object naming from action images, and object naming from object-only images found an activation of a similar network of cortical areas in all three conditions, including bilateral occipito-temporal and parietal regions, and left frontal cortex.

Nevertheless, an rTMS study with stimulation applied at a frequency of 1 Hz over 12 min for a total of 720 pulses reinforced the hypothesis that the left anterior midfrontal cortex is critical for processing verbs, since only stimulation of this region (and not of alternative sites, such as its right hemisphere homologue, the premotor cortex, the pars triangularis of the inferior frontal gyrus) increased response latencies for verbs, with no effect on nouns (Cappelletti et al., 2008). Nevertheless, a functional specialization within the ventral premotor cortex for observing actions and for observing objects, and a different organization for processing sentences describing actions and objects was found in an fMRI study (Tremblay and Small, 2011).

It has to be noticed that Corina et al. (2005) found, by means of DES, that the distance for the noun-verb sites was of approximately 1 cm, both at the supramarginal gyrus and in the middle superior temporal gyrus. These findings could partly explain the apparent inconsistency in the neurolinguistic literature regarding selective deficits of action and object naming. Indeed, neuroimaging techniques could have failed to observe clear regional differences, due to the proximity of sites producing different patterns of processing for either object or action. Accordingly, a recent meta-analysis (Crepaldi et al., 2013) does not support the popular tenet that verb processing is predominantly based in the left frontal cortex and noun processing relies specifically on temporal regions. Consequently, this finding does not support the idea that verb lexical-semantic representations are heavily based on embodied motoric information, suggesting instead that the cerebral circuits deputed to noun and verb processing lie in close spatial proximity in a wide network including frontal, parietal, and temporal regions (Crepaldi et al., 2013).

The anatomical dissociation between nouns and verbs has been related to different psycholinguistic interpretations, at the semantic, lexical or syntactic-morphological level. The “semantic” account is an application of the functional/sensory theory for selective semantic categories deficits to noun/verb (Bird et al., 2000): semantic information would be organized according to attributes and, therefore, properties concerning visual aspects (which characterize objects) would be stored in the visual processing areas, while motor properties (object use) would be stored in motor control areas. This distinction is mainly based on the degree of imageability, with verbs having a low imageability. In contrast, Bedny and Caramazza (2011) suggest that interactions between word meaning and sensory-motor experience occur in higher-order polymodal brain regions. The other semantic account refers to the fact that prototypical nouns and verbs tend to be objects (visual properties) and actions (action features), respectively (Damasio and Tranel, 1993; McCarthy and Warrington, 1985). Recently, Moseley and Pulvermuller (2014) suggested that in the noun/verb dissociation topographical differences in brain activation, especially in the motor system and inferior frontal cortex, are driven by semantics. The analysis of inferior frontal/insula, precentral and central areas revealed an interaction between lexical class and semantic factors with clear category differences between concrete nouns and verbs but not abstract ones.

Others interpreted the dissociation on (at least in part) grammatical basis (Caramazza and Hillis, 1991; Shapiro and Caramazza, 2003). In particular, Shapiro et al. (2006) suggested that what is partially different in terms of neural networks is where morpho-syntactic processes involving nouns and verbs take place. These authors tried to identify the cerebral regions that become activated when people produce verbs and nouns within short sentences, and found that left temporal areas (more precisely the fusiform gyrus) are activated when nouns are integrated in sentences, while the left prefrontal and superior parietal cortices become active when verbs are integrated in sentences. This suggests that morpho-syntactic processings that are applied to nouns and verbs involve neural networks at least partially segregated.

A final hypothesis suggests that words of different grammatical classes are not neurally separable, but what is separable are words referring to actions vs. words referring to objects (regardless of their grammatical class). The same shared neural network would be engaged in integration processes for both nouns and verbs. The extent to which such a network would be engaged would depend upon the processing demands of the task (e.g., Siri et al., 2008) or by the types of morpho-syntactic processes (Tyler and Marslen-Wilson, 2008).

Given the inconsistency of the literature, we tried to shed light on the (possible) neural correlates of this (if any) dissociation by means of voxel lesions symptom mapping (VLSM), in a consecutive series of patients undergoing brain surgery for temporal, parietal and frontal tumour removal. Performances before and after surgery in naming pictures of objects and actions were compared taking into account lesion lateralization. VLSM analyses were also performed to explore the relationship between lesion location and behavioural performance, with the aim of clarifying whether impairments in naming actions and objects could be associated with lesions in segregated regions.

2. Materials and methods

2.1. Participants

One-hundred two patients (55 male, mean age 42.1, SD 13.19, range 15–74; mean education 13.5 years, SD 3.6, range 5–23) were included in the study. Of these, 37 underwent surgery for a right hemisphere (RH) tumour and 65 for a left hemisphere (LH) one; all but 6 were right-handed (Oldfield, 1971). Presurgical fMRI assessed language lateralization in all patients by means of a word generation and a picture-naming task (Papagno et al., 2011). Only one left-handed patient (VG) showed a moderate right lateralization of language. Forty-three patients had a high-grade glioma (HGG; RH: 12, LH: 31), 49 a

low-grade glioma (LGG; RH: 17, LH: 32) and 10 an evolving low-grade glioma (ELGG; RH: 8, LH: 2), according to the World Health Organization (WHO) classification. RH and LH patients did not differ in tumour volume [$t(72) = 1.58, p = .17$], age [$t(100) = 0.4, p = .69$], or educational level [$t(100) = 0.78, p = .44$]. All patients had no visual recognition, conceptual or articulatory deficits, as assessed by an extensive neuropsychological battery. Moreover, they did not show thematic roles assignment deficits, as assessed by means of a sentence comprehension task (Cecchetto et al., 2012).

2.2. Neuropsychological assessment

An extensive neuropsychological assessment, including Attentional Matrices, Token Test, Raven Colored Progressive Matrices, Verbal Fluency on phonemic and semantic cue (Novelli et al., 1986), as well as a picture naming of objects and a picture naming of action (Papagno et al., 2012), was performed in the week (1–7 days) before and in the week (1–7 days) after surgery.

Picture naming of objects was assessed by means of a subtest from a standardized Semantic Battery developed by Catricalà et al. (2013) (see Fig. S4a for a stimulus example). This task included 48 colored pictures of items from living and non-living categories balanced for semantic category, semantic relevance, familiarity name agreement, picture typicality, image complexity, frequency and familiarity (cut-off 41.48, range 0–48).

Action naming was also a standardized Italian test, which included 50 line drawings of a person performing an action (Crepaldi et al., 2014), with a name agreement $\geq 85\%$; thirteen were inaccusative, 17 intransitive and 20 transitive verbs (see Fig. S4b for a stimulus example). They were matched for frequency with objects. Patients were asked to name what the agent was doing. Note that lexical retrieval was assessed therefore, any response that matched the meaning was accepted, independently from the verb form (i.e., to eat, he eats, etc.). Constructions using auxiliary verbs were not accepted, but synonyms, such as, for example, “sbucciare” and “pelare”, both meaning “to peel”, or “annegare” and “affogare”, both meaning to drown, were accepted (cut-off 36.86; range 0–50).

For both tasks, responses were scored as correct or wrong. See Appendix for a complete list of the experimental stimuli.

2.3. Data analysis

2.3.1. Behavioural performance

Analyses were performed using the statistical software SPSS (version 24; Armonk, NY: IBM Corp). Scores on the neuropsychological tests were analysed by means of mixed Time (pre-/post-surgery) by Hemisphere (left/right) ANOVAs. Post-hoc tests were run on comparisons on estimated marginal means within the ANOVAs, by means of the same software. Bonferroni correction for multiple comparisons was applied.

2.3.2. MRI acquisition and VLSM

MRI was performed pre- and post-operatively on a 3 Tesla MR scanner (Siemens Verio, Erlangen, Germany). Standard MR evaluation for morphological characterization of lesions included axial T2-weighted TSE sequence (TR/TE 3000/85 ms; field of view (FOV), 230 mm; 22 slices; section thickness, 5/1-mm gap; matrix, 512×512 ; SENSE factor, 1.5), axial 3D-FLAIR sequence (TR/TE 10000/110 ms; FOV, 230 mm; 120 slices; section thickness, 1.5/0-mm gap; matrix, 224×256 ; SENSE factor, 2) and postcontrast T1-weighted inversion recovery sequence (TR/TE 2000/10 ms; FOV, 230 mm; 22 slices; section thickness, 5/1-mm gap; matrix, 400×512 ; SENSE factor, 1.5). Lesion volume was calculated with semi-automatic segmentation with region of interest analysis with iPlan Cranial 3.0 software suite (Brainlab, Feldkirchen, Germany). FLAIR hyperintense and gadolinium-enhanced signal abnormalities were included in the lesion load for low-

grade and high-grade gliomas, respectively, and then reported in cm^3 . The extent of resection (EOR) was measured on pre- and post-operative MR performed after surgery, and classified as previously reported (EOR = [(pre-operative volume – post-operative volume) / pre-operative volume] * 100 (Smith et al., 2008). Individual lesion mapping was manually performed by two independent judges (GM and AP) who drew over the lesion boundaries, on each relevant post-surgery T1 MRI axial slice, a volume of interest (VOI) in MRIcron software (www.mricron.com/mricron). All voxels with altered signal, i.e. the regions removed by surgical procedure and adjacent oedema when present (Mattavelli et al., 2017) were included in the VOIs, which were then smoothed in the three planes and inspected by a skilled neurologist (CP) and neurosurgeon (MR). Finally, lesion maps and patients' MRIs were normalized to an MNI T1 template in SPM8 (Ashburner and Friston, 1999).

The NPM software of the MRIcron package (Version 2016) was used to perform voxel-based lesion-symptom mapping (VLSM). Post-surgery VOIs and behavioural scores at the neuropsychological tests were analysed. As in Mattavelli et al. (2017), the choice of analysing the post-surgery performance aimed at linking patients' cognitive abilities with brain damage. Before surgery, indeed, some areas inside the lesion can be functionally active (this is why direct electrical stimulation is performed); therefore, mapping a pre-surgery lesion does not guarantee that we are mapping an inactive region (Karnath and Steinbach, 2011). Similarly, the analysis of the difference between post and pre-surgery scores may only reflect this heterogeneity. Voxel-wise analysis was carried out by means of *t*-tests (Campanella et al., 2014; Mattavelli et al., 2017) only in those voxels damaged in at least three patients (7,109,137 voxels) with a statistical threshold of $p = .05$, applying a Bonferroni correction for unique lesion patterns.

3. Results

3.1. Behavioural results

3.1.1. Neuropsychological assessment

In general, performance decreased after surgery (see Tables 1 and 2 for means and statistical analyses, respectively).

ANOVAs revealed a significant main effect of Time on all the mentioned tests. LH patients performed worse than RH patients in language-related tasks, as the main effect Hemisphere was significant for the Token Test, verbal fluency on phonemic and semantic cue, and for sentence comprehension. The Hemisphere by Time interaction highlighted that performance significantly decreased in LH compared to RH patients in the Token Test, Attentional Matrices, verbal fluency on phonemic and semantic cue and sentence comprehension, while no differences were found in the Raven Colored Progressive Matrices between LH and RH patients.

3.1.2. Picture naming of objects

Considering normative data for picture naming of objects, patients scoring under the cut-off were 3 LH and 3 RH in the pre-surgery assessment, and 28 LH and 2 RH in the post-surgery one. The Time x Hemisphere ANOVA revealed a significant main effect of Time [$F(1,100) = 19.98; p < .001$], being the post-surgery performance worse (mean score = 40.2; SD = 11) than the pre-surgery one (mean score = 45.6; SD = 3.9); also the main effect of Hemisphere was significant [$F(1,100) = 6.03; p = .016$], since RH patients outperformed LH patients (mean scores: 45, SD = 6.1, vs 41.8, SD = 6.5). Crucially, the Time by Hemisphere interaction was significant [$F(1,100) = 16.08; p < .001$]. Post hoc tests showed that LH patients' performance on picture naming of objects significantly decreased after surgery (45.8, SD = 3.1, vs 37.7, SD = 11.9; $p < .001$) but not in RH patients (45.2, SD = 5, vs 44.8, SD = 7.3; $p = .77$). In addition, LH and RH patients' performance did not differ in before surgery ($p = .44$), while it did after tumour resection ($p = .001$; see Fig. 1a).

Table 1

Means and standard deviation (SD) of the left (LBD) and right brain-damaged (RBD) patients in the neuropsychological tests on the pre- and post-surgical assessment.

Test	RBD patients			LBD patients		
	N° patients	Mean	SD	N° patients	Mean	SD
Token Test						
- Pre-surgery	37	31.55	4.47	65	32.2	2.34
- Post-surgery	37	30.13	5.61	65	24.26	7.91
Verbal fluency						
- (Semantic) pre-surgery	35	38.26	9.55	65	39.37	10.58
- (Semantic) post-surgery	36	32.53	8.69	64	24.11	14.77
- (Phonemic) pre-surgery	35	29.17	8.15	65	29.58	11.50
- (Phonemic) post-surgery	36	22.81	11.55	64	15.09	11.51
Sentence comprehension						
- Pre-surgery	27	98%	0.025	32	98%	0.018
- Post-surgery	26	97%	0.03	26	95%	0.06
Attentional matrices						
- Pre-surgery	37	47.81	7.73	65	47.79	7.03
- Post-surgery	37	40.59	9.67	65	34.92	14.45
Raven Colored Progressive Matrices						
- Pre-surgery	37	29.33	4	69	30.42	3.8
- Post-surgery	37	26.43	4.01	69	27.61	4.73

3.1.3. Picture naming of actions

Action naming was not assessed post-surgery in four patients. The behavioural and VLSM analyses were then run on 98 patients. Patients scoring under the cut-off were 3 LH and 3 RH in the pre-surgery assessment, and 29 LH and 6 RH in the post-surgery one. Similarly to picture naming of objects, the Time by Hemisphere ANOVA showed a significant main effect of Time [$F(1,96) = 36.7$; $p < .001$], being post-surgery scores lower (mean score = 37.7; SD = 10.7) than pre-surgery ones (mean score = 44.3; SD = 5.4); also the main effect Hemisphere [$F(1,96) = 5.6$; $p = .019$] was significant, being RH patients' scores higher than LH patients' ones (mean scores: 42.9, SD = 7.6, vs 40, SD = 6.5). Finally, the Time by Hemisphere interaction was significant [$F(1,96) = 18.4$; $p < .001$]: while LH and RH patients performed at a similar level before surgery (44.4, SD = 3.7, vs 43.9, SD = 7.7; $p = .73$), as for objects, after tumour resection LH patients' performance significantly decreased compared to RH patients' one (35, SD = 11.2, vs 42.1 SD = 7.9; $p = .001$). LH patients' post-surgery scores, indeed,

Table 2

Statistical analyses of patients' performance on the neuropsychological tests.

Test	df	F	p	Partial eta 2
Token Test				
Time	1, 100	52.74	< .001	0.34
Hemisphere	1, 100	7.56	.007	0.07
Time × Hemisphere	1, 100	25.61	< .001	0.20
Verbal fluency (semantic cue)				
Time	1, 80	12.88	.001	0.139
Hemisphere	1, 80	6.8	.01	0.078
Time × Hemisphere	1, 80	0.58	.45	0.007
Verbal fluency (phonemic cue)				
Time	1, 97	60.08	< .001	0.382
Hemisphere	1, 97	3.88	.038	0.038
Time × Hemisphere	1, 97	10.03	.002	0.094
Sentence comprehension				
Time	1, 98	5.98	.016	0.058
Hemisphere	1, 98	3.17	.078	0.031
Time × Hemisphere	1, 98	4.76	.032	0.046
Attentional matrices				
Time	1, 100	72.29	< .001	0.42
Hemisphere	1, 100	2.47	.112	0.024
Time × Hemisphere	1, 100	5.71	.019	0.054
Raven Colored Progressive Matrices				
Time	1, 98	49.3	< .001	0.335
Hemisphere	1, 98	1.97	.16	0.02
Time × Hemisphere	1, 98	0.029	.86	0

significantly differed from pre-surgery ones ($p < .001$), while RH patients' scores did not ($p = .27$; see Fig. 1b).

3.2. VLSM results

Fig. 2a shows the lesion overlap for the 102 patients. Obviously, according to the patients' selection, the maximum lesion overlap was found in the fronto-temporo-insular regions. In Fig. 2b the regions with

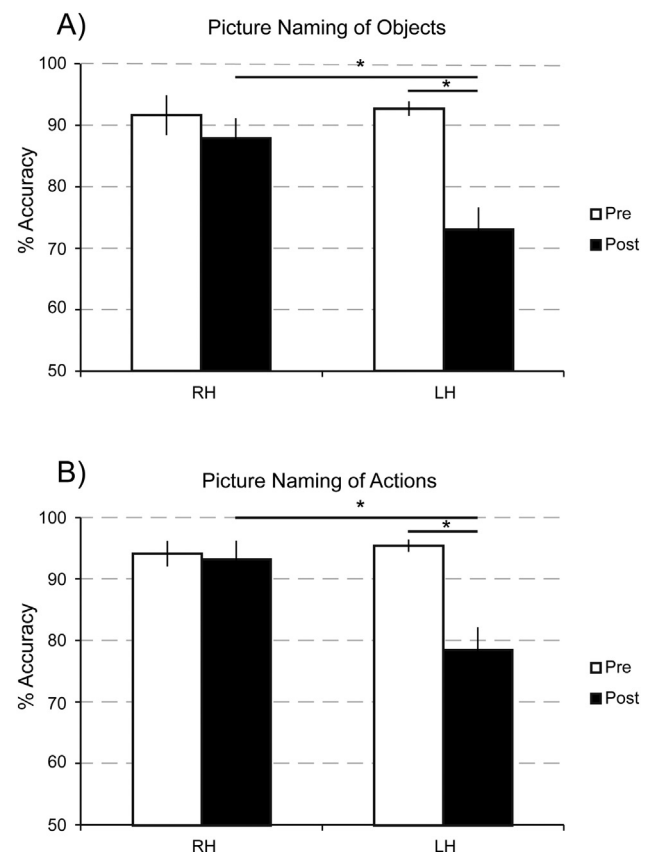


Fig. 1. Performance of right (LH) and left hemisphere (RH) patients on picture naming of objects (A) and actions (B). Vertical bars represent standard error of the means; asterisks highlight significant results in post-hoc analyses for the significant Time × Hemisphere interaction.

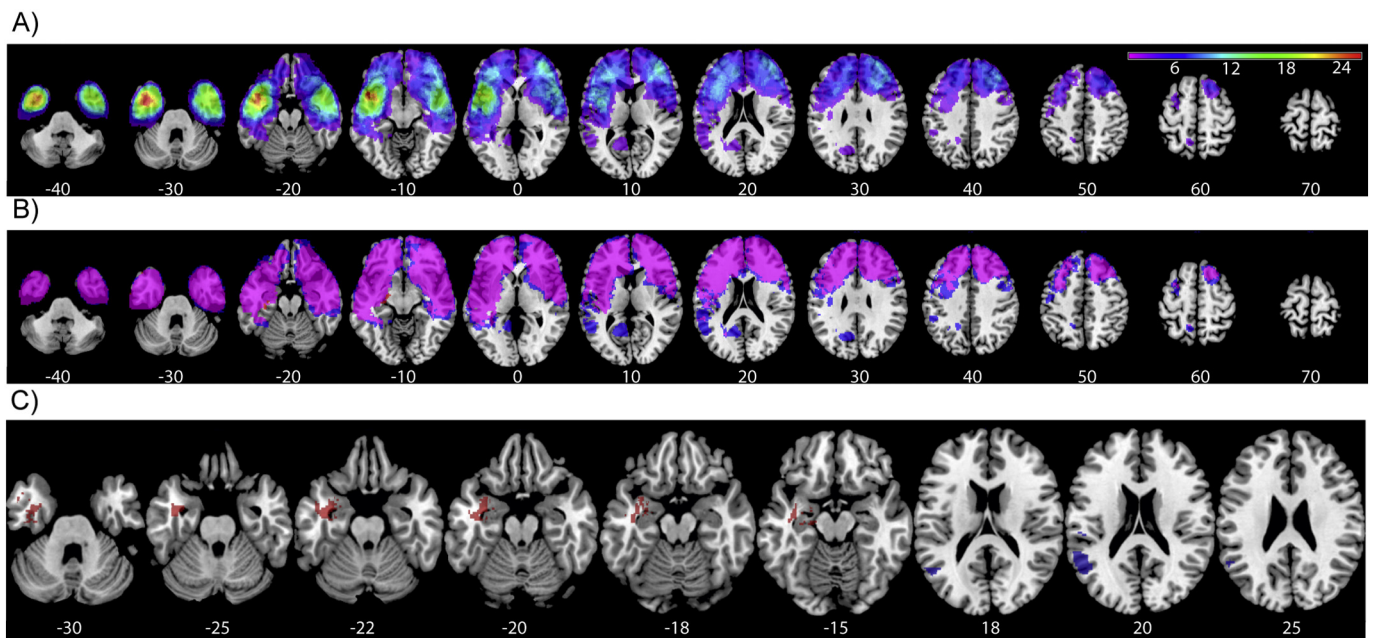


Fig. 2. Results of the VLSM analyses at the picture naming tasks. (A) Lesion maps of 102 patients. Color bar indicates the number of overlapping lesions in each voxel; left hemisphere (LH) is on the left side and right hemisphere (RH) on the right side of the images. (B) Maps of regions with statistical power of 0.8 in the VLSM analyses. Pink areas represent overlapping power maps for picture naming of objects and verbs. Blue areas are regions with 0.8 power for the Picture Naming of Objects task only. (C) Results of VLSM analyses for objects (red) and actions (blue) picture naming. (For interpretation of the references to color in this figure legend, the reader is referred to the web version of this article.)

a statistical power of 0.8 in the VLSM analyses on picture naming of objects and action are represented.

Both tests showed a significant left-sided lesion-behaviour correlation (nouns: *t*-test range -2.9 – 6.38 , *Z* score threshold = 4.56; verbs: *t*-

test range -3.32 – 4.67 , *Z* score threshold = 4.53); however, inside the left hemisphere, specific sites for object and actions were spatially segregated. Picture naming of objects deficits were linked to damaged voxels in the left inferior middle and superior temporal gyrus, the

Table 3
Voxel-based lesion–symptom mapping results for object naming.

Object naming									
Index	Area	N>0	%N>0	Sum>0	Mean>0	Max	MaxX	MaxY	MaxZ
0	Not cortical	1620	0,000288	75385,41	0,013392	6,338009	-40	-10	-21
89	Temporal_Inf_L	972	0,037899	53622,41	2,090787	6,044359	-42	-10	-24
37	Hippocampus_L	433	0,057973	16214,84	2,170952	5,819884	-33	-4	-27
55	Fusiform_L	337	0,018382	19413,14	1,058918	6,378164	-39	-8	-24
85	Temporal_Mid_L	184	0,004676	50195,62	1,275522	5,540484	-42	-2	-27
41	Amygdala_L	132	0,076168	5844,02	3,372199	5,167499	-23	-3	-13
83	Temporal_Pole_Sup_L	78	0,007626	18321,36	1,791294	5,19508	-31	6	-22
81	Temporal_Sup_L	56	0,003059	27832,37	1,520313	5,166825	-38	-9	-7
39	ParaHippocampal_L	39	0,004942	11059,46	1,401529	4,918922	-31	-10	-24
29	Insula_L	33	0,002196	24931,17	1,659312	5,166825	-37	-9	-7
87	Temporal_Pole_Mid_L	33	0,005515	12715,78	2,124963	5,061547	-47	10	-31

Subcortical pathways

For Speculative Brodmann Map: 0=not cortical and 48=no Brodmann label									
Index	Area	N>0	%N>0	Sum>0	Mean>0	Max	MaxX	MaxY	MaxZ
0	Unclassified	469	0,000532	41452,16	0,047024	6,378164	-38	-8	-24
45	Uncinate_fasciculus_	19	0,404255	190,8201	4,060001	5,108708	-32	0	-20
33	External_capsule_R	12	0,016461	1484,897	2,036896	5,081907	-36	-8	-12
31	Sagittal_stratum_(in	9	0,031469	625,4899	2,187028	5,429827	-40	-14	-18
39	Fornix_(cres)/_Stri	5	0,036496	239,2063	1,746031	5,247717	-32	-6	-18

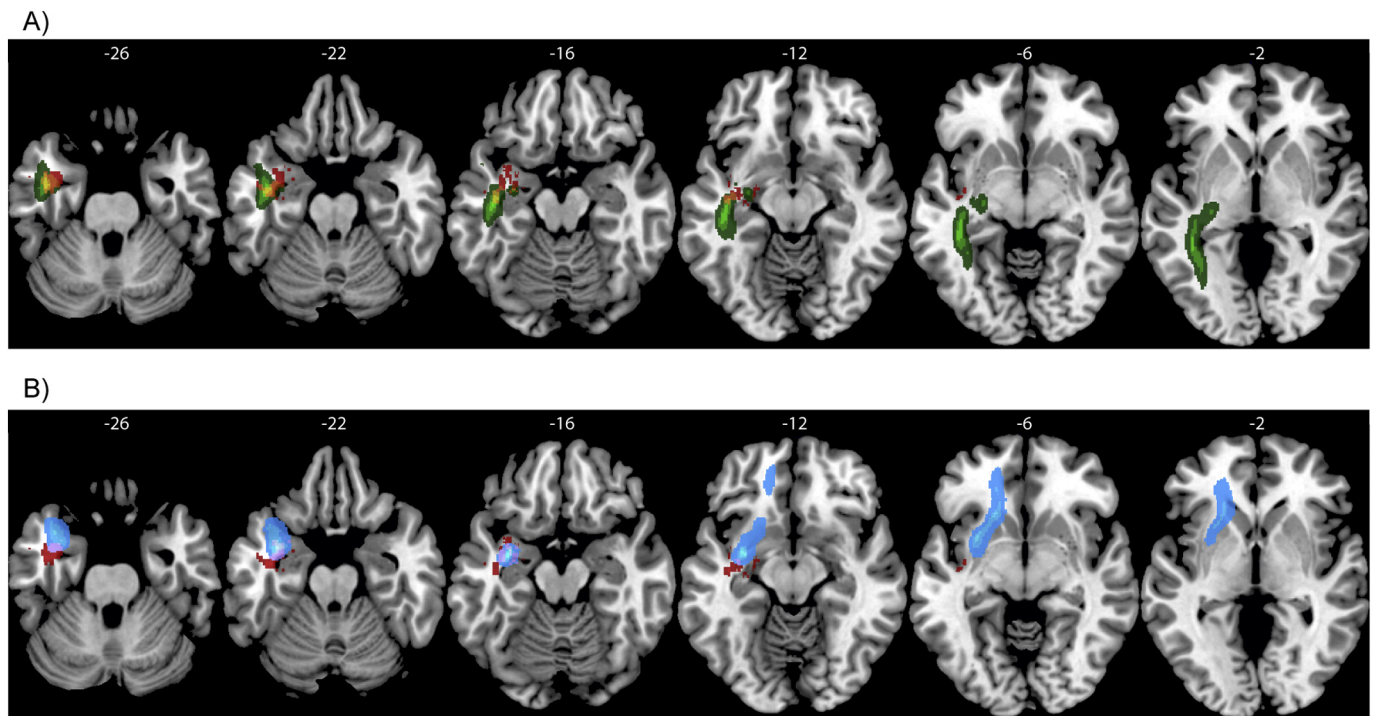


Fig. 3. Results of VLSM analyses for Picture Naming of Objects (in red) superimposed on (A) the left ILF (in green; yellow voxels represent overlapping regions) and (B) the left Uncinate Fasciculus (in cyan, violet voxels represent overlapping regions) taken from the template of subcortical tracts (Catani and Thiebaut de Schotten, 2008). (For interpretation of the references to color in this figure legend, the reader is referred to the web version of this article.)

Table 4
Voxel-based lesion–symptom mapping results for action naming.

Action naming									
Index	Area	N>0	%N>0	Sum>0	Mean>0	Max	MaxX	MaxY	MaxZ
85	Temporal_Mid_L	803	0,020405	36401,09	0,924989	4,583582	-54	-51	15
81	Temporal_Sup_L	104	0,005681	21270,79	1,161894	4,609326	-52	-28	20
63	SupraMarginal_L	95	0,009589	2773,844	0,279988	4,609326	-56	-26	20
65	Angular_L	18	0,001933	94,86388	0,010186	4,583582	-44	-54	23
17	Rolandic_Oper_L	17	0,002141	6995,775	0,881191	4,609326	-50	-28	21
89	Temporal_Inf_L	4	0,000156	35958,46	1,402053	4,60521	-42	-5	-27
0	Not cortical	3	5,33E-07	53385,18	0,009484	4,667598	-40	-7	-24
55	Fusiform_L	3	0,000164	14379,5	0,784351	4,562143	-39	-7	-24

hippocampus, the anterior part of the fusiform gyrus, the superior temporal pole, the amygdala and the insula (see Fig. 2c and Table 3). Crucially, damage to subcortical pathways was linked to picture naming of objects. In particular, damage to the uncinate fasciculus and, to a greater extent, to the inferior longitudinal fasciculus, led to a worse performance in this task (see Fig. 3a and b and Table 3; for a 3D rendering of the results, see Fig. S3).

Conversely, regions associated with a deficit in picture naming of actions involved more posterior regions of the left hemisphere, including the posterior middle and superior temporal gyrus, the supramarginal and angular gyri, and, marginally, the rolandic operculum (see Fig. 2c and Table 4).

VLSM was performed also on a series of other neuropsychological tests to verify selectivity, namely the fact that performance was not generally impaired in all tasks after brain damage in that site. There was no significant correlation between brain damage and cognitive performance for the Raven Colored Progressive Matrices, Attentional

Matrices, sentence comprehension and verbal fluency on phonemic cue, while VLSM analysis showed a significant correlation between deficits in verbal fluency on semantic cue and damaged voxels in the left anterior middle and inferior temporal gyri, middle and superior temporal pole, the fusiform gyrus, the amygdala, the hippocampus and parahippocampal gyrus (t -test range -3079 – 5188 , Z score threshold = 4.56; see Fig. 4a and Table 5).

Finally, voxels in the posterior part of the left superior and middle temporal gyri as well as the angular and supramarginal gyri were correlated with impaired Token Test (t -test range -3705 – 4697 , Z score threshold = 4.56; see Fig. 4b; for overlapping voxels of the VLSM for different tasks see Figs. S1 and S2).

4. Discussion

We assessed performance on action and object naming in patients with left or right hemisphere tumour before and after surgery for its

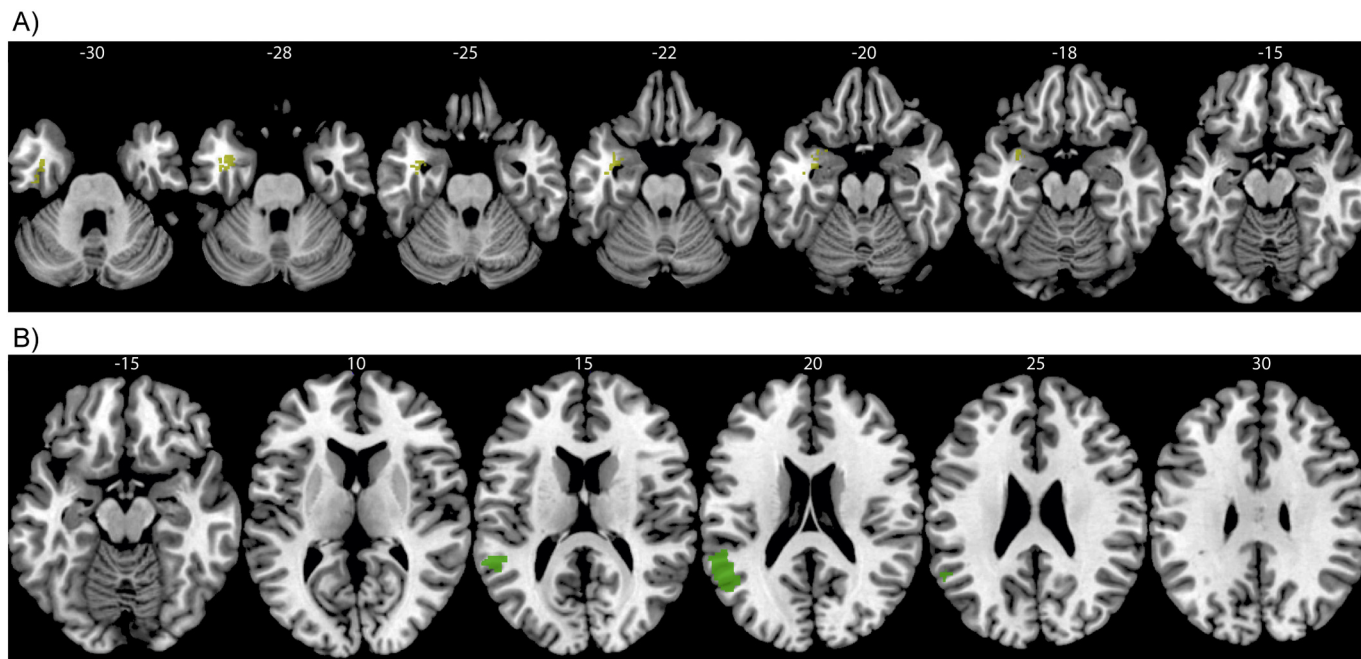


Fig. 4. Results of VLSM analyses for (A) the Verbal fluency on semantic cue (yellow) and (B) the Token Test (green). (For interpretation of the references to color in this figure legend, the reader is referred to the web version of this article.)

Table 5
Voxel-based lesion–symptom mapping results for verbal fluency on semantic cue.

Verbal fluency on semantic cue									
Index	Area	N>0	%N>0	Sum>0	Mean>0	Max	MaxX	MaxY	MaxZ
0	Not cortical	443	7,87E-05	79380,55	0,014102	5,107423	-42	-5	-24
89	Temporal_Inf_L	270	0,010528	42910,18	1,673107	5,03505	-42	-4	-27
55	Fusiform_L	74	0,004036	18418,97	1,004689	5,187588	-39	-7	-24
83	Temporal_Pole_Sup_L	57	0,005573	20714,23	2,025248	5,052906	-31	5	-19
37	Hippocampus_L	30	0,004017	10925,17	1,462736	4,942249	-33	-4	-27
41	Amygdala_L	17	0,00981	5392,285	3,111532	5,052906	-31	4	-19
87	Temporal_Pole_Mid_L	16	0,002674	11003,44	1,838809	4,588205	-30	7	-36
85	Temporal_Mid_L	14	0,000356	37290	0,947577	4,769607	-42	-2	-27
39	ParaHippocampal_L	7	0,000887	10107,2	1,280852	4,66087	-28	-8	-29

Subcortical

Index	Area	N>0	%N>0	Sum>0	Mean>0	Max	MaxX	MaxY	MaxZ
0	Unclassified	112	0,000127	43278,29	0,049096	5,056029	-38	0	-26
45	Uncinate_fasciculus_5	0,106383	175,2643	3,729027	4,756124	-32	0	-20	

Token Test									
Index	Area	N>0	%N>0	Sum>0	Mean>0	Max	MaxX	MaxY	MaxZ
85	Temporal_Mid_L	972	0,0247	47115,5	1,197253	4,697416	-54	-51	15
81	Temporal_Sup_L	537	0,029333	22838,78	1,247544	4,697416	-62	-47	16
63	SupraMarginal_L	20	0,002019	2293,322	0,231485	4,697416	-59	-48	24
65	Angular_L	18	0,001933	97,79385	0,010501	4,697416	-44	-54	23
0	Not cortical	1	1,78E-07	58171,93	0,010334	4,670862	-47	-45	16

removal. The lesion–behaviour relationship was also examined.

LH and RH patients did not differ before surgery in neuropsychological tests and in tumour volume. However, in LH patients, neuropsychological performance significantly decreased post-surgery, as

already noticed in this type of patients (Papagno et al., 2012), while RH patients' performance remained stable. In particular, post-surgery scores significantly decreased for both nouns and verbs only in LH patients, being impaired approximately the 30% of them.

Concerning the anatomical correlates of these deficits in object and action naming, we found significant VLSM results in the LH for the two naming tasks. Crucially, VLSM showed two segregated regions accounting for patients' behaviour: object naming was related to lesions in a region that included the inferior temporal gyrus, the hippocampus, the anterior part of the fusiform gyrus, and, to a lesser extent, the amygdala and the anterior middle and superior temporal gyrus, while action naming impairment involved a region including the posterior middle and superior temporal gyrus, the supramarginal gyrus, and, marginally, the rolandic operculum and the angular gyrus. These results support previous neuropsychological findings of left lateralized and distinct neural correlates for object and action naming (Kemmerer et al., 2012; Tranel et al., 2001); moreover, they demonstrate that noun-verb anatomo-functional dissociation can be found also in brain tumour patients despite the possible reorganization occurring in these patients (Duffau, 2011). A similar VLSM study conducted on stroke patients (Baldo et al., 2013) has shown that a large network in left peri-Sylvian cortex supports picture naming, but that the left mid-posterior middle temporal gyrus and underlying white matter play a critical role in the core ability to retrieve a name associated with an object or picture. Other VLSM studies investigated recognition of action words by means of a word-video matching task (and not naming as in our study), and found that performance in a semantic gesture recognition task was predicted by damage to the posterior temporal lobe, whereas the spatial gesture recognition task was predicted by damage to the inferior parietal lobule (Kalénine et al., 2010). Similar anatomical results were obtained by Tarhan et al. (2015) for both action production and action recognition. Our results on action naming, i.e. the involvement of the middle temporal gyrus and inferior parietal cortex, are also in line with those obtained in a meta-analysis on functional neuroimaging studies on semantic processing in which a specific contrast was performed on types of conceptual knowledge (Binder et al., 2009). In this study an ALE analysis run on 40 activation foci reported by 10 studies specifically investigating action processing, indeed, revealed significant overlap in the left ventral supramarginal gyrus and left middle temporal gyrus.

There are, however, some issues that deserve further discussion. The first point is the finding concerning object naming. The majority of the reported patients with selective disorders of noun processing had retro-rolandic lesions, in particular involving the left temporal lobe (see Cappa and Perani, 2003 for a review). Damasio and Tranel (1993) reported patients with the lesion location carefully assessed by means of MRI, and demonstrated that a patient with an impairment only for nouns, had bilateral mesial and lateral temporal lesions, while a second one, with a similar dissociation, had a left anterior temporal lesion. Later, Damasio et al. (1996) demonstrated that abnormal retrieval of words for animals correlated with damage to the left inferior temporal gyrus, while abnormal retrieval of words for tools correlated with damage to a postero-lateral inferior temporal gyrus and the temporo-parietal-occipital junction. Finally, patients with anterior temporal lobectomy were found to be impaired in naming objects but not verbs (Glosser and Donofrio, 2001). Regarding neuroimaging studies, Price et al. (1996) by means of PET associated areas specific to object naming with left temporal extrasylvian regions, left anterior insula and right cerebellum.

Our results are in line with these previous studies, but further specified the temporal regions involved in object naming. Crucially, new insight is provided on the role of subcortical structures in this task. Lesions to the left inferior longitudinal fasciculus, indeed, has been found to impair performance, suggesting that this long tract might be crucial, together with the uncinat fasciculus, in retrieving and selecting the correct lexical information, stored in the middle and inferior portions of the temporal lobe.

The second point deserving consideration is a lack of correlation between action naming and frontal regions damage (see for example Damasio and Tranel, 1993), as was already found in several

neuropsychological studies (De Renzi and Di Pellegrino, 1995; Silveri and Di Betta, 1997; Luzzatti et al., 2006), and in a meta-analysis performed on neuroimaging studies (Crepaldi et al., 2013). Our results, indeed, suggest an involvement in picture naming of actions of the posterior temporal lobe and supramarginal gyrus. A careful investigation of previous studies, however, shows that the correlation between action naming and these more posterior regions is not new, although it is the link with frontal lesions that has always been stressed. For example, Martin et al. (1996) found an activation of the left middle temporal gyrus by action word generation. In contrast to our findings, Tranel et al. (2001) found maximal overlap in the left frontal operculum in 22 patients who failed an action naming task (and compared to patients who passed it), but converging with our results also in the supramarginal gyrus, portions of the posterior middle temporal gyrus, and the white matter underlying all of these regions. Notably, many of the patients who failed the action naming task passed a separate object naming task. Similarly, Kemmerer et al. (2012) found, in 61 patients with lesions due to different etiologies, that action naming was linked with the cortex and underlying white matter of several left-hemisphere regions, including the inferior frontal gyrus. However, in line with our results, also the supramarginal gyrus, and the posterior middle temporal gyrus, posterior inferior temporal and lateral occipital gyri, and posterior fusiform and lingual gyri were involved. A substantial proportion of the patients with action naming deficits had normal naming of the object categories that were tested (animals, fruits/vegetables, and tools). This dissociation substantiates our findings of segregated underlying neural substrates for actions and objects.

The supramarginal gyrus involvement in action naming found in the previous literature and in our study, is particularly interesting: for example, Sirigu et al. (2004) showed that patients with parietal lesions can report when they started moving, but not when they first became aware of their intention to move. They thus proposed that when a movement is planned, activity in the parietal cortex generates a predictive internal model of the upcoming movement. Yet, supramarginal gyrus lesions are associated with ideomotor apraxia (Goldenberg, 2009), which is related to manipulation of object and action processing and this is consistent with our finding of a role of the supramarginal gyrus in action processing. Moreover, the left supramarginal gyrus has been linked with the planning of complex visually guided actions (see Kemmerer et al., 2012 for a detailed discussion). Finally, Tettamanti et al. (2005) showed that listening to transitive sentences describing concrete object-directed actions (e.g., I grasp the knife) engaged the left supramarginal gyrus.

A further support to the role of the left supramarginal gyrus in action naming comes from a tDCS study on corticobasal degeneration (Manenti et al., 2015), in which anodal tDCS applied over the left parietal cortex decreased reaction time during action naming. Interestingly, a recent multivoxel pattern analysis study (Wurm and Lingnau, 2015) reported that this region seems to be specifically involved in the abstract representation of actions, suggesting a role in high-order semantic action representation.

All these data suggest a distributed network for action words that probably includes frontal, parietal and temporal regions. However, frontal regions are involved in syntactic processing (Kaan and Swaab, 2002; see for example a meta-analysis in Vigneau et al., 2006, showing evidence of a cortical area in the pars opercularis of the inferior frontal gyrus dedicated to syntactic processing) and it could well be the case that the frontal involvement is related to morphosyntactic processing applied to verbs.

Also, we must underline that large parts of the language ventral stream (that includes the inferior fronto-occipital fasciculus, the uncinat fasciculus and the inferior longitudinal fasciculus) were not covered by lesions present in our patients. Therefore, we cannot exclude that a lesion in (for example) the posterior inferior temporal gyrus would result in a disproportionate deficit to process object names, too.

Finally, a relevant result was that VLSM analyses carried out

considering the scores on non-linguistic neuropsychological tests (Attentional Matrices and Raven Colored Progressive Matrices) were not significant. This finding demonstrates that the regions associated with deficits in naming, namely the inferior, middle and superior temporal gyri, the anterior part of the fusiform gyrus, the supramarginal gyrus, the angular gyrus and the hippocampus, were not generally engaged in all cognitive tasks. In other words, the VLSM result was specific for the two tasks of interest. Similarly, verbal fluency on phonemic cue did not show any correlation with these regions. However, being this task more related to executive functions, this result is, at least in part, expected. Conversely, the same regions supporting picture naming of objects, namely the anterior part of the inferior, middle, superior temporal lobe as well as the fusiform gyrus and the hippocampus, were involved in verbal fluency on semantic cue. This is not surprising, since verbal fluency on semantic cue requires lexical-semantic processing which probably relies on the same retrieval mechanism guiding picture naming of objects.

A final comment concerns the time point of imaging and behavioural testing that we chose. Karnath and Rennig (2017) tested the validity of the three common combinations (acute, post-acute and chronic) of structural imaging data and behavioural scores used in VLSM analyses. They found that only the combination of acute behavioural scores and acute structural imaging produced accurate results in revealing the emergence of hemiparesis after stroke, because chronic patients with recovery from hemiparesis do not provide valid results. Indeed, Karnath and Rennig suggest that VLSM studies that use the patients' chronic behaviour should measure patients' behaviour both in the acute and the chronic phases to exclude those patients who initially suffered from the deficit of interest but have significantly recovered. An interesting approach would be to analyze patients' behaviour in the chronic phase and imaging from the acute phase to reveal the neural correlates of chronic dysfunction.

Indeed, if the aim of a VLSM lesion analysis is to uncover the neural substrates of a certain function in the healthy human brain, the use of chronic behavioural data appears to be inadequate because of possible reorganization. These results were obtained with stroke patients but the same line of reasoning can be adopted for neurosurgical patients: post-surgery scores directly reflect the cognitive consequences of brain resection, without the possible intervention of a plastic reorganization, which has been found to occur in tumour patients at 3-months follow-up testing (Papagno et al., 2016). Similarly, pre-surgery scores may, or not, be impaired by the presence of the tumoral lesion (since, as mentioned in the introduction, there can be functional areas inside the tumour), being thus, in our opinion, not reliable. Therefore, we consider the VLSM studies performed by Piras and Marangolo (2007) (six months after stroke and only 16 patients) and by Campanella et al. (2010) (only 30 patients with left or right lesions, relating MRI before surgery with scores before or after surgery) quite questionable.

5. Conclusions

In conclusion, our results on a very large series of patients suffering a disease with the same type of aetiology showed an object/action dissociation, confirming its relevance in our tasks. In line with the previous literature, our data suggest that temporal regions are involved in naming objects, while, in contrast with the dominant view we found no evidence of frontal involvement but more posterior temporal regions and the supramarginal gyrus in naming actions.

Supplementary data to this article can be found online at <https://doi.org/10.1016/j.nicl.2018.03.022>.

Acknowledgments

The authors are grateful to Francesca Righetti and Amanda Tedone for helping in lesion mapping.

Funding

This research did not receive any specific grant from funding agencies in the public, commercial or not-for-profit sectors.

Conflicts of interest

None.

References

- Aggularo, S., Crepaldi, D., Pistarini, C., Taricco, M., Luzzatti, C., 2006. Neuroanatomical correlates of impaired retrieval of verbs and nouns: interaction of grammatical class, imageability and actionality. *J. Neurolinguistics* 19, 175–194.
- Ashburner, J., Friston, K.J., 1999. Nonlinear spatial normalization using basis functions. *Hum. Brain Mapp.* 7, 254–266.
- Baldo, J.V., Arevalo, A., Patterson, J.P., Dronkers, N.F., 2013. Grey and white matter correlates of picture naming: evidence from a voxel-based lesion analysis of the Boston Naming Test. *Cortex* 49, 658–667.
- Baxter, D.M., Warrington, E.K., 1985. Category specific phonological dysgraphia. *Neuropsychologia* 23, 653–666.
- Bedny, M., Caramazza, A., 2011. Perception, action, and word meanings in the human brain: the case from action verbs. *Ann. N. Y. Acad. Sci.* 1224, 81–95.
- Binder, J.R., Desai, R.H., Graves, W.W., Conant, L.L., 2009. Where is the semantic system? A critical review and meta-analysis of 120 functional neuroimaging studies. *Cereb. Cortex* 19, 2767–2796.
- Bird, H., Howard, D., Franklin, S., 2000. Why is a verb like an inanimate object? Grammatical category and semantic category deficits. *Brain Lang.* 72, 246–309.
- Campanella, F., D'Agostini, S., Skrap, M., Shallice, T., 2010. Naming manipulable objects: anatomy of a category specific effect in left temporal tumours. *Neuropsychologia* 48, 1583–1597.
- Campanella, F., Shallice, T., Ius, T., Fabbro, F., Skrap, M., 2014. Impact of brain tumour location on emotion and personality: a voxel-based lesion-symptom mapping study on mentalization processes. *Brain* 137, 2532–2545. <http://dx.doi.org/10.1093/brain/awu183>.
- Cappa, S.F., Perani, D., 2003. The neural correlates of noun and verb processing. *J. Neurolinguistics* 16, 183–189.
- Cappelletti, M., Fregni, F., Shapiro, K., Pascual-Leone, A., Caramazza, A., 2008. Processing nouns and verbs in the left frontal cortex: a transcranial magnetic stimulation study. *J. Cogn. Neurosci.* 20, 707–720.
- Caramazza, A., Hillis, A.E., 1991. Lexical organization of nouns and verbs in the brain. *Nature* 349, 788–790.
- Catani, M., Thiebaut de Schotten, M., 2008. A diffusion tensor imaging tractography atlas for virtual in vivo dissections. *Cortex* 44, 1105–1132.
- Catricalà, E., Della Rosa, P.A., Ginex, V., Mussetti, Z., Plebani, V., Cappa, S.F., 2013. An Italian battery for the assessment of semantic memory disorders. *Neurol. Sci.* 34, 985–993.
- Cecchetto, C., Di Domenico, A., Garraffa, M., Papagno, C., 2012. Comprendo. Batteria per la comprensione di frasi negli adulti. Raffaello Cortina Editore, Milano.
- Corina, D.P., Gibson, E.K., Martin, R., Poliakov, A., Brinkley, J., Ojemann, G.A., 2005. Dissociation of action and object naming: evidence from cortical stimulation mapping. *Hum. Brain Mapp.* 24, 1–10.
- Crepaldi, D., Berlinger, M., Cattinelli, I., Borghese, N.A., Luzzatti, C., Paulesu, E., 2013. Clustering the lexicon in the brain: a meta-analysis of the neurofunctional evidence on noun and verb processing. *Front. Hum. Neurosci.* 7, 303.
- Crepaldi, D., Casarotti, A., Zarino, B., Papagno, C., 2014. How to become twice more precise in detecting neuropsychological impairments. In: *Front. Psychol. Academy of Aphasia*.
- Damasio, A.R., Tranel, D., 1993. Nouns and verbs are retrieved with differently distributed neural systems. *Proc. Natl. Acad. Sci.* 90, 4957–4960.
- Damasio, H., Grabowski, T.J., Tranel, D., Hichwa, R.D., Damasio, A.R., 1996. A neural basis for lexical retrieval. *Nature* 380, 499–505.
- Daniele, A., Barbier, A., Di Giuda, D., Vita, M.G., Piccininni, C., Spinelli, P., Tondo, G., Fasano, A., Colosimo, C., Giordano, A., Gainotti, G., 2013. Selective impairment of action-verb naming and comprehension in progressive supranuclear palsy. *Cortex* 49, 948–960.
- De Renzi, E., Di Pellegrino, G., 1995. Sparing of verbs and preserved, but ineffectual reading in a patient with impaired word production. *Cortex* 31, 619–636.
- Duffau, H., 2011. Do brain tumours allow valid conclusions on the localisation of human brain functions? *Cortex* 47, 1016–1017. <http://dx.doi.org/10.1016/j.cortex.2010.11.010>.
- Glosser, G., Donofrio, N., 2001. Differences between nouns and verbs after anterior temporal lobectomy. *Neuropsychology* 15, 39–47.
- Goldenberg, G., 2009. Apraxia and the parietal lobes. *Neuropsychologia* 47, 1449–1459.
- Goodglass, H.H., Klein, B., Carey, P., Jones, K., 1966. Specific semantic word category in aphasia. *Cortex* 2, 74–89.
- Kaan, E., Swaab, T.Y., 2002. The brain circuitry of syntactic comprehension. *Trends Cogn. Sci.* 6, 350–356.
- Kalénine, S., Buxbaum, L.J., Branch Coslett, H., 2010. Critical brain regions for action recognition: lesion symptom mapping in left hemisphere stroke. *Brain* 133, 3269–3280.
- Karnath, H.-O., Rennig, J., 2017. Investigating structure and function in the healthy

- human brain: validity of acute versus chronic lesion-symptom mapping. *Brain Struct. Funct.* 222, 2059–2070. <http://dx.doi.org/10.1007/s00429-016-1325-7>.
- Karnath, H.-O., Steinbach, J.P., 2011. Do brain tumours allow valid conclusions on the localisation of human brain functions? *Objections. Cortex* 47, 1004–1006. <http://dx.doi.org/10.1016/j.cortex.2010.08.006>.
- Kemmerer, D., Rudrauf, D., Manzel, K., Tranel, D., 2012. Behavioral patterns and lesion sites associated with impaired processing of lexical and conceptual knowledge of actions. *Cortex* 48, 826–848.
- Liljeström, M., Tarkiainen, A., Parviainen, T., Kujala, J., Numminen, J., Hiltunen, J., Laine, M., Salmelin, R., 2008. Perceiving and naming actions and objects. *NeuroImage* 41, 1132–1141.
- Lubrano, V., Filleron, T., Démonet, J.-F., Roux, F.-E., 2014. Anatomical correlates for category-specific naming of objects and actions: a brain stimulation mapping study. *Hum. Brain Mapp.* 35, 429–443.
- Luzzatti, C., Aggujaro, S., Crepaldi, D., 2006. Verb-noun double dissociation in aphasia: theoretical and neuroanatomical foundations. *Cortex* 42, 875–883.
- Manenti, R., Bianchi, M., Cosseddu, M., Brambilla, M., Rizzetti, C., Padovani, A., ... Cotelli, M., 2015. Anodal transcranial direct current stimulation of parietal cortex enhances action naming in corticobasal syndrome. *Front. Aging Neurosci.* 7, 49. <http://dx.doi.org/10.3389/fnagi.2015.00049>.
- Martin, A., Wiggs, C.L., Ungerleider, L.G., Haxby, J., 1996. Neural correlates of category-specific knowledge. *Nature* 379, 649–652.
- Mattavelli, G., Pisoni, A., Casarotti, A., Comi, A., Sera, G., Riva, M., Bizzi, A., Rossi, M., Bello, L., Papagno, C., 2017. Consequences of brain tumour resection on emotion recognition. *J. Neuropsychol.* <http://dx.doi.org/10.1111/jnp.12130>.
- McCarthy, R., Warrington, E.K., 1985. Category specificity in an agrammatic patient: the relative impairment of verb retrieval and comprehension. *Neuropsychologia* 23, 709–727.
- Miceli, G., Silveri, M.C., Villa, G., Caramazza, A., 1984. On the basis for the agrammatic's difficulty in producing main verbs. *Cortex* 20, 207–240.
- Miceli, G., Silveri, M.C., Nocentini, U., Caramazza, A., 1988. Patterns of dissociations in comprehension and production of nouns and verbs. *Aphasiology* 2, 351–358.
- Moseley, R.L., Pulvermuller, F., 2014. Nouns, verbs, objects, actions, and abstractions: local fMRI activity indexes semantics, not lexical categories. *Brain Lang.* 132, 28–42.
- Novelli, G., Papagno, C., Capitani, E., Laiacona, M., Vallar, G., Cappa, S.F., 1986. Tre test clinici di ricerca e produzione lessicale: taratura su soggetti normali [three clinical tests of verbal long-term memory: standardization on normal subjects]. *Arch. Psicol. Neurol. Psichiatr.* 47, 477–506.
- Oldfield, R.C., 1971. The assessment and analysis of handedness: the Edinburgh Inventory. *Neuropsychologia* 9, 97–113.
- Papagno, C., Gallucci, M., Casarotti, A., Castellano, A., Falini, A., Fava, E., Giussani, C., Carrabba, G., Bello, L., Caramazza, A., 2011. Connectivity constraints on cortical reorganization of neural circuits involved in object naming. *NeuroImage* 55, 1306–1313.
- Papagno, C., Casarotti, A., Comi, A., Gallucci, M., Riva, M., Bello, L., 2012. Measuring clinical outcomes in neuro-oncology. A battery to evaluate low-grade gliomas (LGG). *J. Neuro-Oncol.* 108, 269–275. <http://dx.doi.org/10.1007/s11060-012-0824-5>.
- Papagno, C., Casarotti, A., Comi, A., Pisoni, A., Lucchelli, F., Bizzi, A., Riva, M., Bello, L., 2016. Long-term proper name anomia after removal of the uncinate fasciculus. *Brain Funct. Struct.* 221, 687–694. <http://dx.doi.org/10.1007/s00429-014-0920-8>.
- Peelen, M.V., Romagno, D., Caramazza, A., 2012. Independent representations of verbs and actions in left lateral temporal cortex. *J. Cogn. Neurosci.* 24, 2096–2107.
- Perani, D., Cappa, S.F., Schnur, T., Tettamanti, M., Collina, S., Rosa, M.M., Fazio, F., 1999. The neural correlates of verb and noun processing. *Brain* 122, 2337–2344.
- Petersen, S.E., Fox, P.T., Posner, M.I., Mintun, M., Raichle, M.E., 1989. Positron emission tomographic studies of the processing of single words. *J. Cogn. Neurosci.* 1, 153–170.
- Pillon, A., d'Honinchtun, P., 2011. The organization of the conceptual system: the case of the “object versus action” dimension. *Cogn. Neuropsychol.* 27, 587–613.
- Piras, F., Marangolo, P., 2007. Noun-verb naming in aphasia: a voxel-based lesion-symptom mapping study. *Neuroreport* 18, 1455–1458.
- Price, C.J., Moore, C.J., Humphreys, G.W., Frackowiak, R.S.J., Friston, K.J., 1996. The neural regions sustaining object recognition and naming. *Proc. Biol. Sci.* 263, 1501–1507.
- Shapiro, K., Caramazza, A., 2003. Looming a loom: evidence for independent access to grammatical and phonological properties in verb retrieval. *J. Neurolinguistics* 16, 85–111.
- Shapiro, K.A., Mottaghy, F.M., Schiller, N.O., Poeppel, T.D., Flü, M.O., Müller, H.W., ... Krause, B.J., 2005. Dissociating neural correlates for nouns and verbs. *NeuroImage* 24, 1058–1067.
- Shapiro, K.A., Moo, L.R., Caramazza, A., 2006. Cortical signatures of noun and verb production. *Proc. Natl. Acad. Sci.* 103, 1644–1649.
- Silveri, M.C., Di Betta, A.M., 1997. Noun-verb dissociations in brain-damaged patients: further evidence. *Neurocase* 3, 477–488.
- Siri, S., Tettamanti, M., Cappa, S.F., Rosa, P.D., Saccuman, M.C., Scifo, P., et al., 2008. The neural substrate of naming events: effects of processing demands but not of grammatical class. *Cereb. Cortex* 18, 171–177.
- Sirigu, A., Daprati, E., Ciancia, S., Giroux, P., Nighoghossian, N., Posada, A., Haggard, P., 2004. Altered awareness of voluntary action after damage to the parietal cortex. *Nat. Neurosci.* 7, 80–84.
- Smith, J.S., Chang, E.F., Lamborn, K.R., Chang, S.M., Prados, M.D., Cha, S., ... Berger, M.S., 2008. Role of extent of resection in the long-term outcome of low-grade hemispheric gliomas. *J. Clin. Oncol.* 26, 1338–1345. <http://dx.doi.org/10.1200/JCO.2007.13.9337>.
- Tarhan, L.Y., Watson, C.E., Buxbaum, L.J., 2015. Shared and distinct neuroanatomic regions critical for tool-related action production and recognition: evidence from 131 left-hemisphere stroke patients. *J. Cogn. Neurosci.* 27, 2491–2511.
- Tettamanti, M., Buccino, G., Saccuman, M.C., Gallese, V., Danna, M., Scifo, P., Fazio, F., Rizzolatti, G., Cappa, S.F., Perani, D., 2005. Listening to action-related sentences activates fronto-parietal motor circuits. *J. Cogn. Neurosci.* 17, 273–281.
- Tranel, D., Adolphs, R., Damasio, H., Damasio, A.R., 2001. A neural basis for the retrieval of words for actions. *Cogn. Neuropsychol.* 18, 655–670.
- Tremblay, P., Small, S.L., 2011. From language comprehension to action understanding and back again. *Cereb. Cortex* 21, 1166–1177.
- Tyler, L.K., Marslen-Wilson, W., 2008. Fronto-temporal brain systems supporting spoken language comprehension. *Philos. Trans. R. Soc. Lond. Ser. B Biol. Sci.* 363, 1037–1054.
- Tyler, L.K., Russell, R., Fadili, J., Moss, H.E., 2001. The neural representation of nouns and verbs: PET studies. *Brain* 124, 1619–1634.
- Vigneau, M., Beaucousin, V., Hervé, P.Y., Duffau, H., Crivello, F., Houdé, O., Mazoyer, B., Tzourio-Mazoyer, N., 2006. Meta-analyzing left hemisphere language areas: phonology, semantics, and sentence processing. *NeuroImage* 30, 1414–1432.
- Warburton, E., Wise, R.S., Price, C.J., Weiller, C., Hadar, U., Ramsay, S., Frackowiak, R.S.J., 1996. Noun and verb retrieval by normal subjects. *Studies with PET. Brain* 119, 159–179.
- Wurm, M.F., Lingnau, A., 2015. Decoding actions at different levels of abstraction. *J. Neurosci.* 35, 7727–7735.
- Zingeser, L.B., Berndt, R.S., 1990. Grammatical class and context effect in a case of pure anomia: implications for models of language production. *Cogn. Neuropsychol.* 64, 475–516.